

# The use of narrow implants

**Author:** Dr Huub van't Veld

The development of very narrow implants can provide a solution for interdental spaces in the aesthetic zone that are smaller than 5–6 mm and in which implantology is indicated to fill the diastema with an implant-supported crown. Increasingly, in the choice of the implant not only the quantity (> 1 mm) and quality of the surrounding bone are important but also the support function of the bone to obtain a good mucosal seal. The major implant brands have developed small diameter implants for these narrow spaces. Nobel has the 3.0 mm NobelActive implant, about which many publications have already appeared; Astra has the OsseoSpeed 3.0 mm implant and DENTSPLY has the Xive 3.0 implant.

In 1976, the FDA already defined implants with a diameter of 3.0 mm and greater as conventional dental implants. In 1997, this institute defined implants with a diameter smaller than 3.0 as SDI (small diameter implants). This mainly concerns one piece implants used in very narrow jaws for a removable device or as an anchor for orthodontics. These implants often consist of one piece due to the fragility of the connection between the implant and abutment in such a narrow diameter. Unfortunately, they offer too few options for a crown because it is not possible to choose abutments with different angles for a perfect prosthetic solution. Therefore, the practitioner has to choose an implant with a sepa-

rate abutment. Most narrow implants have a conical connection between the implant and abutment. This connection is screwed together. Stress tests have shown that the screw is the most limiting factor with stress. A solid abutment and a conical connection with a Morse taper of sufficient length and a cone of between 1.5 and 4 degrees result in a nearly leak-proof and rigid connection between abutment and implant. This is a so-called 'cold weld'. This makes such an implant almost as strong as a one-piece implant.

I would like to talk you through the treatment procedure for two patients I treated with a 2.8 mm Anthogyr Axiom implant, and share the final result with you.

## Case 1

The first patient was referred to me by her dentist due to a persistent 53 (Fig. 1), which occasionally caused pain and also began to show mobility. 13 is agenetic, as is 23, which I had already replaced with an implant with a crown in 2011 (Fig. 2). At the time, the left side of the upper jaw still had sufficient space for a 3.4 mm implant (Ankylos). In the top right at 53, I only measured an interdental space of 4.8 mm. I decided to use a 12x2.8 mm implant with 4 mm 1.5° Morse taper. I chose this implant on the one hand be-

**Fig. 1:** Initial situation with the strongly resorbed 53 in situ.

**Fig. 2:** OPT at intake.

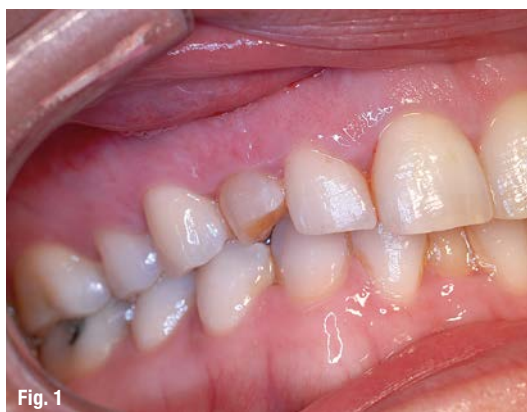

Fig. 1

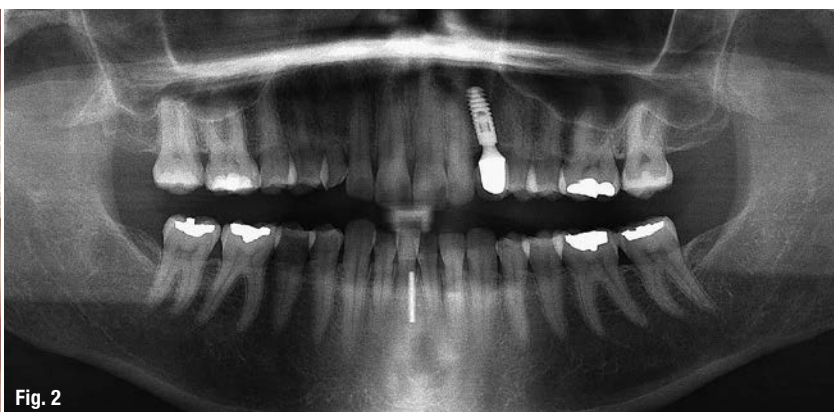


Fig. 2

cause the manufacturer promised that considerable primary stability could be achieved due to the aggressive threading in the lower third section of the implant, and on the other hand because I had to deal with a very short residual root of the 53. The latter allows a small extraction alveole and thus sufficient bone for a good primary stability, and thus the possibility of inserting a temporary crown immediately after implantation.

### Procedure

I removed element 53 atraumatically; the mesial and distal papillae remained intact. By using a very sharp osteotome (Netwig) as a guide, I determined the location (more to palatal) and the direction of the preparation (Fig. 3). I gently tapped this osteotome to approximately 8 mm (according to calibration) into the jaw bone, and by rotating it slightly, I achieved a good guide preparation. After this, I used the Dentak K-system for further preparation (Fig. 4). This set consists of a hollow drill shaft containing a grinder in which, during further preparation, the bone is collected and then used to fill the space around the preparation and the residual alveolar bone. I drilled to no more than two-thirds of the desired preparation length. The narrowest K-drill has a 3.2 mm diameter so that the preparation at the top is slightly wider than the 2.8 mm implant to be used. This gives the option to adjust the implant somewhat in the axial direction if necessary. I used a 2.6 drill of the Anthogyr implant system (Fig. 5) to bring the preparation to the correct length. The total length of the preparation is 13 mm so that the implant can be placed 1 mm under the bone edge (Fig. 6). There is very good primary stability ( $>35$  Ncm) (Fig. 9).

After fitting a temporary abutment made of PEEK (polyether ether ketone, Fig. 7), I made a temporary composite crown. The PEEK temporary abutment is easy to construct using composite or temporary resin. This temporary abutment also has a  $1.5^\circ$  Morse taper, which provides good friction retention and does not damage the cone in the implant. Before placing the temporary crown, I applied the bone obtained in the hollow drill shaft on the labial side and condensed it so that the alveolus is filled properly (Fig. 8). The temporary crown was shaped in such a way in the cervical area that the alveolus was completely covered. Of course, I checked that no functional stress occurred (Fig. 10). At the follow-up check a week later, a good adaptation of the mucosa was already visible. The patient had no problems at all.

After ten weeks, I removed the temporary crown with abutment. This is easy using a crown removal pliers vertically. Using a pop-in impression coping, I made an impression in a closed tray. The lab then

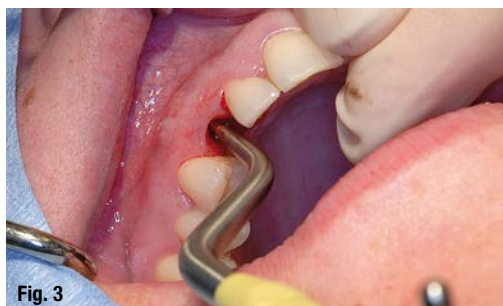

Fig. 3

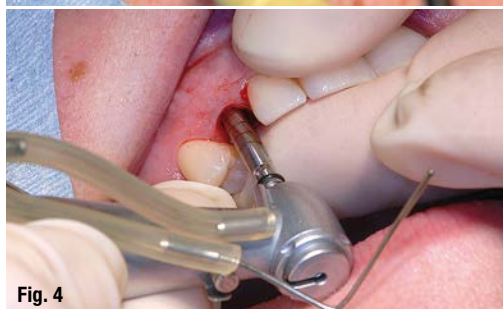

Fig. 4

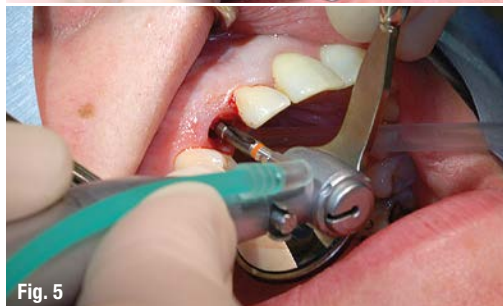

Fig. 5

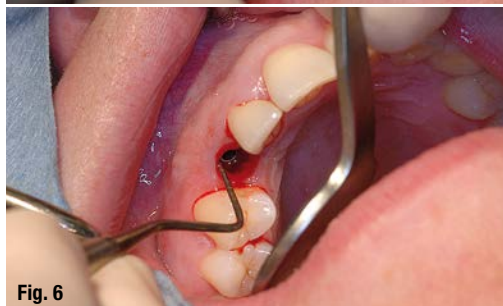

Fig. 6

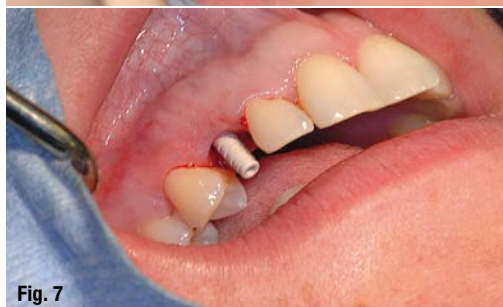

Fig. 7

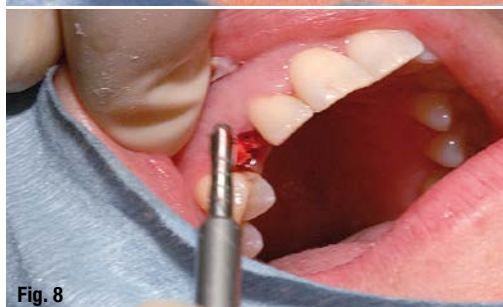

Fig. 8

**Fig. 3:** The preparation was performed precisely using Netwig-osteotome.

**Fig. 4:** The autologous bone was crushed and harvested using the Dentak K-system.

**Fig. 5:** The preparation was inserted at the depth using a 2.6 drill.

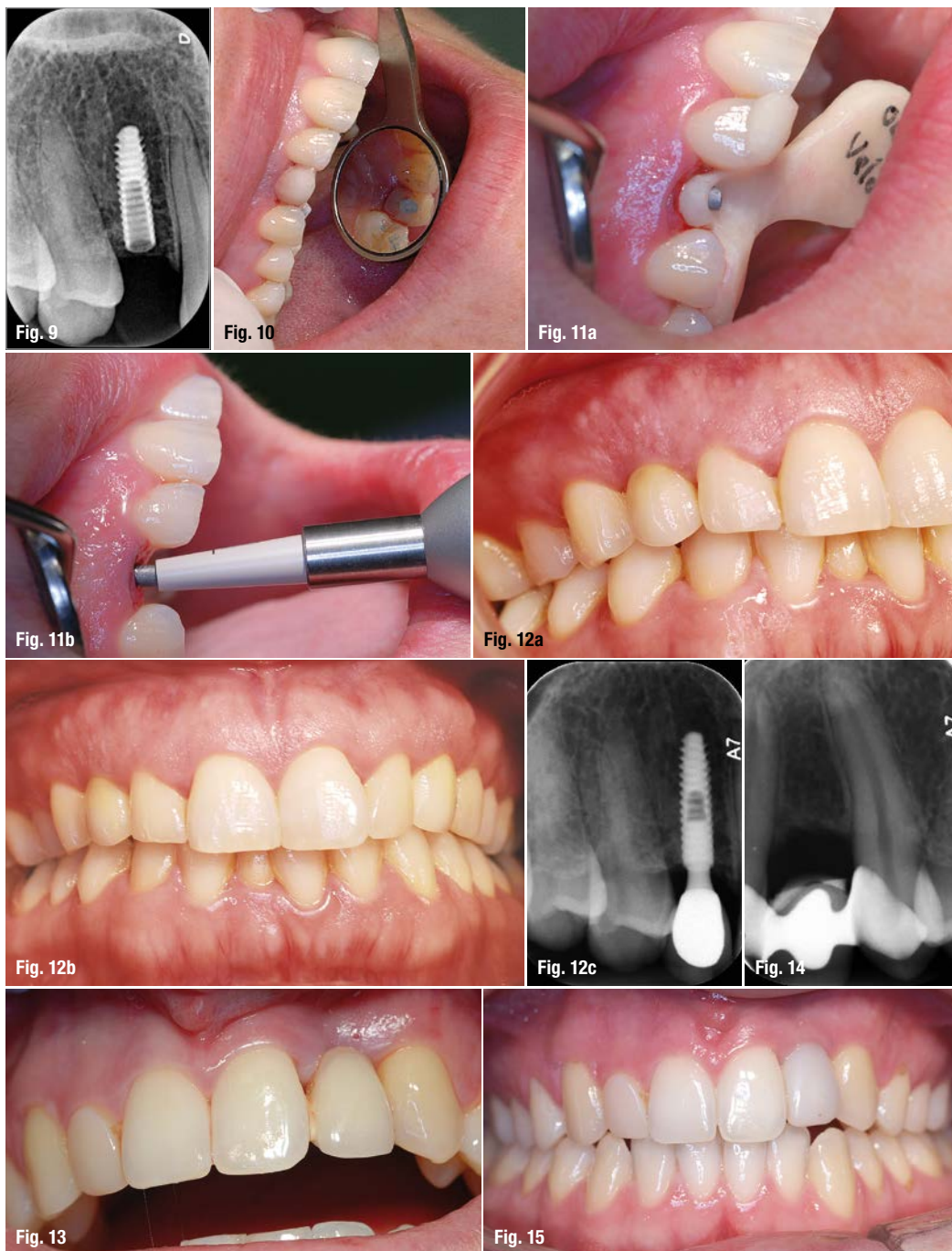**Fig. 6:** Insertion of the implant 1 mm under the bone crest level.

**Fig. 7:** The PEEK abutment in situ.

**Fig. 8:** The harvested bone was attached around the implant with Dentak K.



- Fig. 9:** X-ray after implantation.  
**Fig. 10:** The temporary crown in situ.  
**Fig. 11:** a) Transfer of the abutment with a transfer key, b) structure impaction using Safe Lock.  
**Fig. 12:** a) Result six months after starting treatment; b) result 20 months after starting treatment; c) X-ray 24 months after starting treatment.  
**Fig. 13:** Clinical image of the initial situation with bonded bridge in situ.  
**Fig. 14:** X-ray of the initial situation.  
**Fig. 15:** Clinical image after six months with temporary solution.



made the permanent crown. The temporary crown with PEEK abutment was easily repositioned. In this case, I arranged for the crown to be returned from the lab separately from the abutment. The construction then had to be fitted from the model of the mouth with a transfer key (Fig. 11a) because the structure is not indexed (therefore, it can be cemented in several ways because there is no internal indexation such as a trilob or internal hex). After fitting the crown, which was optimum in both colour and shape, the structure was 'fixed' using Safe-Lock (Fig. 11b). This device is connected to the micro-motor and gives short micro-strokes after activation using the foot pedal. Five strokes are enough to lock

the abutment in place in the implant. The cold weld is then complete. I then cemented the crown accurately in the mouth with luting cement. At the six-month (Fig. 12a) and 20-month (Figs. 12b-c) check-ups, a good adaptation of the mucosa was seen, and the results were considered to be good.

## Case 2

The second patient (25 years of age) approached me at the initiative of a dental student who had read an interview about my first experiences with narrow implants. This patient was no longer satisfied with the bonded bridge that replaced her 22 due to agenesis.

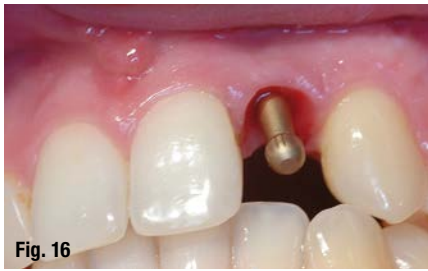

Fig. 16

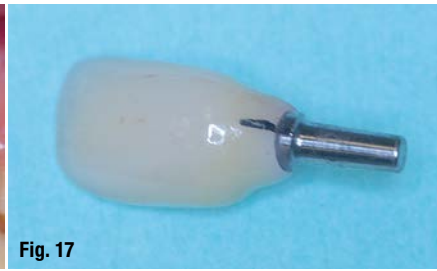

Fig. 17



Fig. 18

**Fig. 16:** Insertion of a pop-in impression after removal of the temporary crown. – **Fig. 17:** Bonding of the permanent crown. – **Fig. 18** Safe Lock with tips.

She also found that her jaw increasingly had a 'dent' at that location (Fig. 13). The X-ray taken at intake showed significant convergence of the radices of 21 and 23. The interdental space was 7.4 mm but only 5.2 mm apical (Fig. 14). I approached this challenge with a 2.8 mm implant. I immediately took an impression to make a temporary crown later.

#### Procedure

After I had removed the bonded bridge, I made a crestal sulcular incision, after which I tried to remove as little mucosa as possible. Again, I started by making a guide with the osteotome (Netwig) which allowed me to determine the position and direction. By always using a slightly larger condenser, I very carefully pressed the labial wall down. As there was no large alveolus (no extraction had been done), applying autologous bone using the Dentak K-system was not necessary, and I only needed to use the condensation technique. Again, the preparation was made to the correct length using the 2.6 drill. I made a direct temporary crown on a PEEK abutment and paid much attention in the cervical area to creating the shape and a proper emergence profile. In this case, an additional complication was that I had to convince the patient of the robustness and reliability of the temporary crown because of her six-months stay in Africa immediately after insertion of the temporary crown on

the implant. I was able to give her my experience that I gained from seven implants using this method as an assurance.

After six months, she returned to the practice and said that she had not experienced any problems. I observed a good adaptation of the mucosa (Fig. 15). After removing the temporary crown, I made a pop-in impression coping (Fig. 16), which also showed an excellent emergence profile with healthy mucosa. The lab again provided the structure with the separate crown. However, in this case, I decided to insert the crown as a whole after having fitted it satisfactorily and bonded it outside the mouth. This allowed me to avoid any embedding of cement residues (Fig. 17). However, I did exercise some restraint because I now had to tap the Safe-Lock directly on the zirconium dioxide porcelain crown to fix the abutment. A special attachment is available for this, which allowed fixing to take place without a problem (Fig. 18).

For this patient, I paid much attention to the cervical gingival line. The 12 was a cone tooth that was constructed with composite, and that was too small. I corrected the patient's cervical gingival line satisfactorily with an electrotome and reconstructed element 12 with composite. This achieved a good result (Figs. 19–20a).

## Hipro-Oss<sup>®</sup>

patented bovine  
bone graft composite

each granule is a composite of  
30% Atelo-Collagen Type I and  
70% hydroxyapatite

conductive and inductive  
properties

excellent handling

atelo-peptidized

lyophilized

haemostatic properties

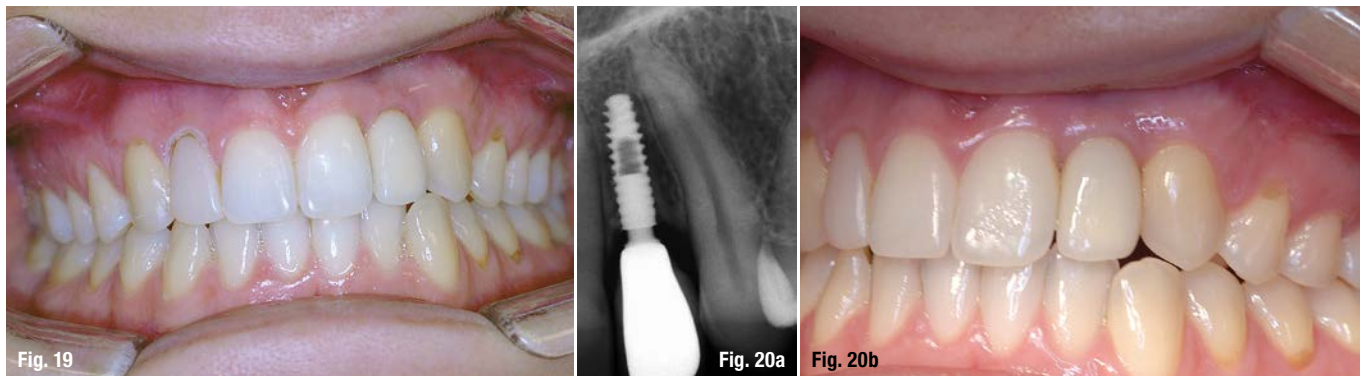
bacteriostatic properties



**bioimplon** GmbH  
Biotech Innovation Pioneers

Friedrich-List-Str. 27  
35398 Giessen, Germany  
+49 (0) 641 6868 1123  
www.bioimplon.de





**Fig. 19:** Clinical picture immediately after insertion of the permanent crown and adjustment of gingival line.

**Fig. 20a:** X-ray image three months after inserting the crown.

**Fig. 20b:** Clinical image three months after inserting the crown.

## Conclusion and commentary

I inserted the first 2.8 implant in 2013. Initially, I had some doubts about implants of such small diameter and had questions such as: Is the construction strong enough? Will it not break? Will the abutment-implant connection remain intact? However, although the use of such narrow implants remains a challenge, it has so far only yielded positive results. Nevertheless, I would like to make some comments following these experiences:

1. All the major brand implant systems marketing narrow implants have paid much attention to the root shape of the implant with windings that have a condensing effect. This significantly increases the primary stability, which enhances osseointegration.
2. This primary stability also results in greater usability in immediate placement and also provides the option to make a temporary crown immediately.
3. The PEEK abutment used in this system has proven to allow trouble-free retention over a longer time. Because in this case, the implant was placed subcrestally and despite the small space, there is still enough bone around, I observed good support of the mucosa and the presence of a good mucosal seal. In this case, a 2.8 mm platform was used as a superstructure with a platform switch. As a result, a proper emergence profile was achieved with the temporary crown.
4. Particularly with regard to reduced mesiodistal spaces, the use of an implant with a small diameter is a solution, but only in the aesthetic zone, where no extreme transverse stress can be placed on the implant.
5. I believe that with excessive stress and large forces, because the implant is so narrow, the abutment-implant connection could be the limiting factor.
6. The faciolingual bone thickness is less restrictive in the application of a narrow diameter implant because with several techniques, such as bone-splitting, harvested autologous bone with the Dentak K-system or possibly with a bone graft, more volume can be created in a less invasive way.

7. To achieve a good result, it is necessary for the practitioner to have the choice of different abutments. Therefore, one of the two-piece implant systems will be chosen. A narrow one-piece implant is less suitable for the aesthetic zone.
8. The solid connection between abutment and implant with the morse taper connection is indeed strong and gives no risk of screw fracture, but there is no way back. The implant becomes a 'one-piece implant' with the solid abutment. By using a grade 5 titanium, strength is also assured: extensive stress tests have been carried out up to 200 N. The positioning and permanent fixing of the restoration do require more attention than with a screwed abutment. For instance, a break in the crown may only be repaired by taking the abutment as a new impression of the crown stump. It is unfortunate that only titanium abutments are available (due to the strength). However, this is so narrow that there is enough body for the crown to make this aesthetically pleasing.

The use of a narrow implant in a very limited space requires a well thought-out diagnosis, great precision of work, and a good use of and experience with different implant techniques. These practical examples did not use any guided surgery, but this could be recommended for precise implant positioning.

## contact

### Dr Huub van't Veld

Engelstraat 3  
6922 JG Duiven,  
Netherlands  
Tel.: +31 316 282502  
tandartsvtveld@planet.nl  
www.tandartsvtveld.nl

Author details